

Chapter

Off-Pump Coronary Artery Bypass (OPCAB), the New Conventional Coronary Artery Bypass (CCAB) Technique

Murali P. Vettath, Arunachalam Vellachamy Kannan, Ganagadharan Nitin, Siddegowda Nagaraju Gururkirana, Korothe Smera, Raman Gopalakrishnan and A.K. Baburajan

Abstract

Coronary artery bypass grafting (CABG), has evolved over the last twenty-five years. Having pioneered this evolution for the last two decades and more, we have moved from an on-pump surgical unit to a completely off-pump surgical unit. This on-pump surgery was in vogue for the past six decades. This was labeled the Conventional CABG (CCAB). We have over the last two decades made off-pump coronary artery bypass (OPCAB) the new CCAB. To make this a reality, we had to invent, innovate, fabricate and modify techniques and technology, so as to make ourselves comfortable to perform all our CABGs without the use of the Heart-lung machine (HLM). We have over the last twenty years performed more than five thousand OPCAB surgeries in this city alone, with a mortality of less than 1%.

In this chapter, we would like to elucidate how one could master this technique of performing OPCAB in all patients who need CABG.

Keywords: CABG, CCAB, OPCAB

1. Introduction

Since 1967, when Rene Favalaro performed the first CABG, using saphenous vein graft (SVG) on an arrested heart [1], at Cleveland clinic, till 1985, when Buffallo [2] and Bennetti [3], published their OPCAB report, on-pump CABG was considered the CCAB. In fact, their publication kindled the fire to develop OPCAB in many surgeons around the world.

Conventional CABG was the gold standard all over the world for the last five decades, probably even now in most of countries. As going on Cardiopulmonary bypass (CPB), stopping the heart and performing the anastomosis on a bloodless and motionless heart was quite a reproducible surgical technique by most of coronary surgeons around the world. This was performed by connecting the heart to the

heart-lung machine, using a cross-clamp on the aorta, and giving Cardioplegia (CP), in the root of the aorta (antegrade CP), or into the coronary sinus (retrograde CP). Then the distal coronary anastomosis was performed in a bloodless and motionless heart. Here, only surgical anastomosis was to be mastered. This became very popular, and this became the CCAB. But with the advent of coronary angioplasty and stenting and the arrival of drug-eluting stents, the number of patients having complications on the HLM started to surface. Basically, the inherent effects of the pump, the inflammatory response, and the development of stroke in the diseased aorta, where cannulations had to be done, and where the cross-clamp had to be used, all became dreaded complications of CABG, and so the number of patients coming for CABG reduced. Cardiologists became the gatekeepers, and so it was time for a change to happen. Hence, with the idea of OPCAB mooted by the South American duo, we in the east started working on how to perform CABG without the use of HLM.

Then in the late 1990s in Utrecht, Netherland, OCTOPUS, the stabilizer was developed, which paved the way for OPCAB to become a reality [4].

2. Anesthetic modifications for OPCAB

Unlike in on-pump CABG, in OPCAB we had to modify our anesthetic technique, to maintain adequate hemodynamics all through surgery. We in fact stop beta blockers on the day of surgery. The main difference between on-pump and off-pump surgery is that in on-pump if the patient crashes during induction, we can go on CPB and revive the patient. We routinely use an internal jugular four-lumen cannula and a radial and femoral arterial line before starting surgery. The femoral arterial line is used to insert the IABP when needed. In OPCAB the anesthetist has to be very vigilant to make sure we do not drop the pressures below a mean of 75 mm of mercury (Hg), all through the procedure. The mean pressure has to be maintained by using small doses of vasopressors, as and when required. Especially when the heart is positioned. It's with a combination of table movement and the use of these vasopressors judiciously, that the anesthetist maintains hemodynamics all through the procedure. The anesthesia is usually maintained by a combination of Fentanyl, Midazolam, Dexmedetomidine, and muscle relaxant cisatracurium. All coronary patients have an infusion of Lasix, during surgery. Routinely our patients are ventilated postoperatively overnight. Once stable, they are weaned and extubated in the morning.

3. OPCAB and its progression

In the nineties, surgeons including us were trying our hand at stabilizing the square centimeter of myocardium that needed to be grafted, using all sorts of instrumentation, which obviously was not reproducible. Then we used to use injection of Adenosine to stop the heartbeat during the crucial stitch on the heel and the toes and restart the heart using pacing wires, etc. Again this technique did not work too.

Only after the Octopus stabilizers came, we could start performing OPCABs routinely. The intracoronary shunts were a very important invention that paved the way for routine use of OPCABs as a procedure of choice.

Initially, our thought was to reduce the heartbeats so that we would have less movement of the heart and we had more time to place our sutures properly. But then we noticed that after using too much of beta blockers, we needed inotropes to get

the heart going in the post-operative period. This we had to tackle by stopping these beta blockers on the day of surgery. As we developed a technique of using Injection Atropine to increase the heart rate, then slowing it down, which improved our hemodynamics, and our stabilizers would do their job by mechanically stopping the movement. This technique was useful for all our anterior wall grafting.

4. Grafting the lateral wall vessels

Then came the issue of grafting the lateral and posterior wall vessels. So, for the lateral wall vessels, we routinely open the right pleura and then cut the pericardium down to the Inferior vena cava (IVC). This allows the right heart to fall into the right chest, while the heart is lifted and verticalized to visualize the lateral wall vessels. Earlier we used the Positioners to lift the apex and tilt the heart, but off late, with experience, we use a deep pericardial stitch [5] to lift the heart up to get easy access to the lateral wall. By doing so the hemodynamics are maintained. Then the stabilizer is placed at the respective positions and the grafting progressed.

5. Grafting the posterior wall vessels

Positioning is important for grafting all these vessels. For the posterior wall, the table is lifted up, and then the head end is dropped as in Trendelenburg position.

If the heart flops too much to the right pleura, then a pericardial stay is used on the detached right pleura to keep the heart vertical. Wet sponges are used to position the heart in the lateral side. Now with the heart positioned, the stabilizer is used to stabilize either the PDA or the PLV as planned. And the grafting progressed as usual.

If the right coronary artery (RCA) is to be grafted, we use a stabilizer with suction pods so that that area to be grafted on the RCA is stabilized and lifted up a bit. So, to say, that, we don't use suction on the pods either for the LAD or the circumflex coronary artery grafts. usually.

For grafting the RCA, we usually use 2 snares of 5.0 prolene suture, one proximal and one distal to the proposed site of the coronary incision. Once the snares are placed, the coronary opening is made and the shunt inserted, then the snares are released, and the grafting is performed as usual. For RCA grafts, the pacing wires are kept ready in case the heart slow.

6. Top-end anastomosis

Usually, the top-end of the vein grafts are performed using a side clamp on the aorta. But in the case of patients with disease aorta, applying a side clamp will lead to dispersing the plaques into the cerebral vessels and causing the stroke. Hence, in patients with the diseased aorta, we had invented our own top-end anastomosing device, the Vettaths anastomotic obturator (VAO) [6]. This has been patented and has been extensively used by us to perform the top end of more than five hundred patients. This has been published in different journals [7]. This is quite useful and does not increase the cost of surgery.

Coming to the top-end anastomosis technique, when we have a patient with chronic renal failure, either on dialysis or with just elevated renal function, OPCAB is

more excellent than going on the pump. In such patients, we try and avoid hypotension as much as possible. In case we need to avoid the hypotension completely, then we use the VAO, where we can still maintain the systolic pressure above 100 mm of Hg. But if the creatinine is below 2 mg/dl, and the ascending aorta is not diseased, then when we use a side clamp, we maintain the systolic pressure between 85 and 90 and perform only one top end of the vein graft, and the other is hooked on to this vein graft as a piggyback. This is such that the mean pressure is attained between, 75 and 80 mm of Hg all the time.

Vettath's technique of mammary patch for diffusely disease LAD without endarterectomy [8].

This is yet another of our innovative technique, in patients who present with diffuse CAD in young age and are deemed inoperable in most centers and are ischemic. We have also published this technique in many journals and are readily available online [8]. The videos are also available in YouTube. The good thing about these techniques are that these patients are able to live a comfortable life without any symptoms. This is a common disease seen in the youth in this part of the world, where stenting is not possible.

7. Role of intra-aortic balloon pump (IABP)

Intra-aortic balloon pump is the most accessible left ventricular assist device that has been in use since its development by Christenson [9, 10]. He had proposed to use the IABP postoperatively initially and later proposed to use it even preoperatively, to stabilize the heart and give a rest to the myocardium, by increasing the coronary flow.

In 2016 [11] we published an article explaining our modification of the role of IABP in OPCAB, which we are still practicing, till date. We have not used IABP, since the day before surgery so far. When the patient is very ischemic with severe ST changes and with hemodynamic instability and complaining of chest pain before induction, we have inserted the IABP, through the Femoral arterial line, which we use to monitor the arterial pressure routinely. This is inflated and this augments the coronary perfusion, thereby preventing ischemia. We give 5000IU of injection heparin to insert this under local anesthesia. Though this is a rare occurrence, we have had to do this in spite of our excellent anesthesia techniques, which we have also standardized over the last two decades.

Most of the time we just insert the femoral arterial line after induction, even in patients with tight left main stenosis, if the patient is hemodynamically stable during induction and is able to maintain a mean blood pressure above 75 mm of mercury(Hg). Hence the use of IABP comes mostly while grafting the lateral wall vessels, that too only in big ischemic obtuse marginal with tight stenosis, proximally and having a dynamic mitral regurgitation noticed in echo preoperatively.

Our grafting techniques are pretty standard, as we first take down the LIMA, skeletonized (<https://www.youtube.com/watch?v=m7mYWLQsDAE>). Then Heparin is given and flow assessed. The radial artery is used for circumflex vessels sometimes. The long saphenous vein is taken as a skip technique, taking care not to cause intimal injury.

Once the LIMA is anastomosed to the LAD, most of the time patient becomes stable. We are then able to lift the heart and position it to expose the lateral wall, using the stitch in the deep pericardial well. If the pulmonary artery pressure goes up by looking at it or we feel that the heart has started distending and is slowing

down, we immediately take the packs out and release the LIMA stitch and increase the heart rate after lifting the head end up, like an anti-Trendelenburg position. This is exactly what the patient would do in his bed when he develops chest pain. Hereby, the left ventricular end-diastolic pressure comes down and reduces the sub-endocardial ischemia. Now the heart looks better. If this is not working, we insert the IABP, without the sheath and inflate it and keep it going till the distal anastomosis of the circumflex vessels are done. We then go in and perform the top end anastomosis, either using a side clamp or the VAO, whichever is found necessary. While performing the top end anastomosis, the IABP is usually in a standby position. Usually, after the top end is performed and the side clamp removed the heart jumps back to normal hemodynamics, and we are able to perform the usual PDA anastomosis even without the IABP. Hence after all the grafting is done, we reverse the Heparin with protamine. After 5 minutes of Heparin reversal, we are usually able to remove the IABP, after inserting another femoral arterial line in the opposite side. This technique has been useful in the sense that we have avoided the conversion on to the HLM in most of the patients. So, to say, over the last 14 years, we had to go on to the heart-lung machine only once. That too, when the patient developed uncontrollable arrhythmia. This patient ended up having the IABP being taken to the cardiac surgical ICU with the patient. Other than this all the IABPs if used in the operation theatre are removed in the OT itself.

From	To	No. of OPCAB	Conversion	IABP	Mortality
Jul-02	Dec-02	47	0	0	0
Jan-03	Dec-03	177	12	0	0
Jan-04	Dec-04	238	6	0	1
Jan-05	Dec-05	299	0	0	3
Jan-06	Dec-06	284	0	4	5
Jan-07	Dec-07	260	1	8	0
Jan-08	Dec-08	225	0	11	2
Jan-09	Dec-09	280	0	8	0
Jan-10	Dec-10	358	0	22	0
Jan-11	Dec-11	413	0	24	0
Jan-12	Dec-12	425	0	23	2
Jan-13	Dec-13	429	0	18	2
Jan-14	Dec-14	312	0	6	3
Jan-15	Dec-15	317	0	6	2
Jan-16	Dec-16	228	0	11	3
Jan-17	Dec-17	109	0	0	0
Jan-18	Dec-18	196	0	0	0
Jan-19	Dec-19	212	1	7	3
Jan-20	Dec-20	128	0	2	2
Jan-21	Dec-21	159	0	1	3
7/4/2002	12/31/2021	5096	20 (0.39%)	151 (2.96%)	31 (0.60%)

This is our modification of IABP, which we have been following. (Chart) [11].

8. Training to be an OPCAB surgeon

Any cardiac surgeon who is interested in becoming an off-pump surgeon, has to first become good on-pump surgeon, and must have an excellent result on-pump, only then should he venture to perform OPCAB.

A perfect coronary anastomosis is the gold standard of CABG. How it's achieved is the prerogative of the surgeon. And depends upon his skill and mindset. Once he is able to dissect a perfect Internal mammary artery, first left and next the right, and to harvest the radial artery and the saphenous veins in that order, and then perform the anastomosis with them, on the pump, only then should he go off-pump.

It is important for the surgeon to visit a good OPCAB center and spend some time there to see how they do it and then try to transfer the technique to his practice.

We started this journey 20 years ago and it took us more than five hundred OPCABs to standardize our technique. When we started off, we were prepared for all eventualities, like going back on pump, whenever we felt it was not safe, or when hemodynamics became bad. Our technique has been elaborated in previous chapters we have published [12].

We had developed our own OPCAB stabilizer, the simple Indian-made stabilizer (SIMS), which has been sent for patenting in 2015. The video link of OPCAB using SIMS in youTube- <https://www.youtube.com/playlist?list=PLmvp6npEfabinhlatq8IYLBz8WIHo8bu1>

We have been routinely using it for all our surgeries over the last thousand five hundred cases. For the last hundred-odd cases. This stabilizer is shown in **Figure 1** below.

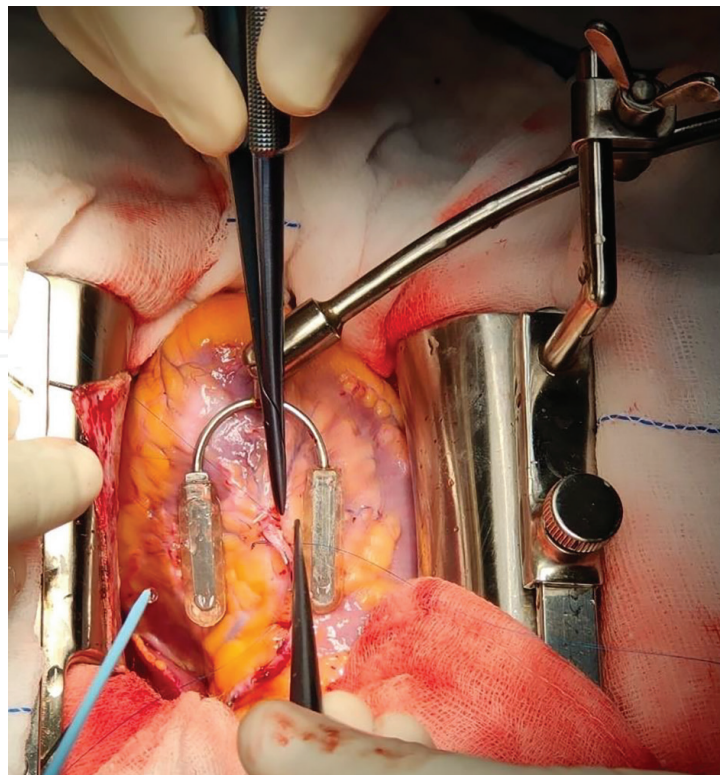


Figure 1.
Shows SIMS with the new Pods.

We started off with first retaining the aortic cannula alone, then when we became confident, that was out as well. And gradually went on and on, and after 20 years and 5000 odd cases, we have had to convert to the heart-lung machine in only one patient in the last 14 years. The reason was the patient developed uncontrolled arrhythmia and could not stabilize with IABP.

9. Future of OPCAB

Minimally invasive and Robotic OPCABs would be the future of coronary revascularization. Though we have performed quite a few of them in this center itself, with multiple grafts, the risk and results are not that as we have in midline sternotomy. Hence, we have set it aside for single or maximum double grafts. We have also developed our own stabilizer for minimally invasive OPCAB too (**Figure 2**).

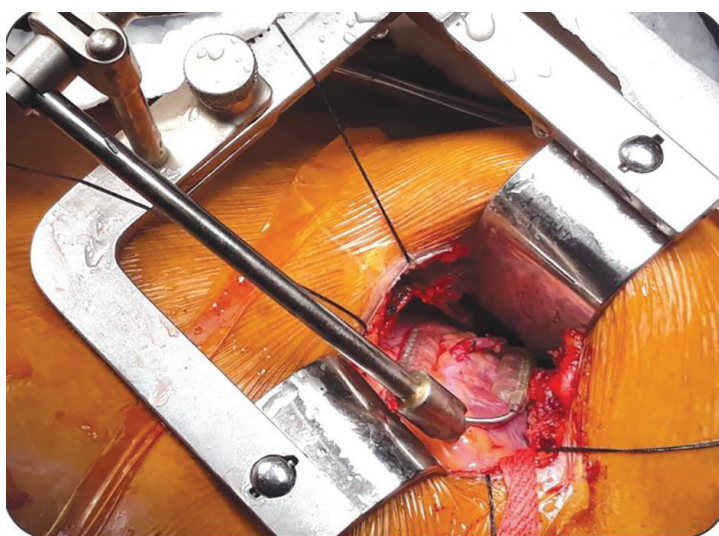


Figure 2.
Shows the modified SIMS for MICS OPCAB.

IntechOpen

Author details

Murali P. Vettath^{1*}, Arunachalam Vellachamy Kannan², Ganagadharan Nitin³, Siddegowda Nagaraju Gururkirana¹, Koroth Smera², Raman Gopalakrishnan² and A.K. Baburajan¹


1 Department of Cardiac Surgery, Meitra Hospital, Kozhikode, Kerala, India

2 Department of Cardiac Anaesthesia, Meitra Hospital, Kozhikode, Kerala, India

3 Department of Anaesthesia, Meitra Hospital, Kozhikode, Kerala, India

*Address all correspondence to: murali.vettath@gmail.com

IntechOpen

© 2022 The Author(s). Licensee IntechOpen. This chapter is distributed under the terms of the Creative Commons Attribution License (<http://creativecommons.org/licenses/by/3.0>), which permits unrestricted use, distribution, and reproduction in any medium, provided the original work is properly cited. 

References

- [1] Favaloro RG. Saphenous vein graft in the surgical treatment of coronary artery disease. *Thoracic Cardiovascular Surgery*. 1968;**58**:178-185
- [2] Buffolo E, Andrade JCS, Succi JE, et al. Direct myocardial revascularization without cardiopulmonary bypass. *Thoracic Cardiovascular Surgery*. 1985;**33**:26-29
- [3] Benetti FJ. Direct coronary surgery with saphenous vein bypass without either cardiopulmonary bypass or cardiac arrest. *Journal of Cardiovascular Surgery*. 1985;**26**:217-222
- [4] Borst C, Jansen EW, Tulleken CA, et al. Coronary artery bypass grafting without cardiopulmonary bypass and without interruption of native coronary flow using a novel anastomosis site restraining device ("Octopus"). *Journal of the American College Cardiology*. 1996;**27**:1356-1364
- [5] Bergsland J, Karamanoukian HL, Soltoski PR, Salerno TA. "Single Suture" for circumflex exposure in OffPump coronary artery bypass grafting. *Annals of the Thoracic Surgery*. 1999;**68**:1428-1430
- [6] Vettath MP. Vettath's anastomotic obturator: A simple proximal anastomotic device. *The Heart Surgery Forum*. 2003;**6**:366-368. Available from: www.hsforum.com/vol6/issue5/2003-73305.html pp-366-368
- [7] Murali VP. Vettath's anastamotic obturator—Our experience of 269 proximal anastamosis. *Heart Lung and Circulation*. 2004;**13**:288-290
- [8] Prabhu AD, Thazhkuni IE, Rajendran S, et al. Mammary patch reconstruction of left anterior descending coronary artery. *Asian Cardiovascular & Thoracic Annals*. 2008a;**16**:313-317
- [9] Christenson JT, Simonet F, Badel P, Schmuziger M. Evaluation of preoperative intra-aortic balloon pump support in high risk coronary patients. *European Journal of Cardiothoracic Surgery*. 1997;**11**:1097-1103
- [10] Christenson J, Simonet F, Badel P, Schmuziger M. Optimal timing of preoperative intraaortic balloon pump support in high-risk coronary patients. *Annals of the Thoracic Surgery*. 1999;**68**:934-939
- [11] Vettath MP et al. Role of intra-aortic balloon pump in off pump coronary artery bypass—A Vettath modification. *World Journal of Cardiovascular Diseases*. 2016;**6**:188-195
- [12] Vettath MP, Vellachamy KA, Ganagadharan N, Ravisankar M, Koroth S, Gopalakrishnan Raman G. Revascularisation strategies in OPCAB (Off Pump Coronary Artery Bypass). DOI: 10.5772/intechopen.88102f 12-PP-91-104